

Early graft thrombosis after endovascular aortic aneurysm repair with aortouni-iliac endografts

L. FERNÁNDEZ-ALONSO, J. OLEA

Endovascular repair of aortic aneurysm has become a viable treatment option in selected patients. However, despite the minimally invasive nature of this treatment a significant incidence of vascular complications has been reported. Here, we report two cases of acute limb ischemia due to endograft thrombosis in patients treated with aortouni-iliac devices and we review the etiologic factors related with these events and the treatment options. We suggest that the presence of atherosclerotic plaques within the outflow arteries and coexistent infrainguinal arterial occlusive disease (poor runoff) is an underestimated factor in the risk of graft thrombosis, especially in patients treated with aortouni-iliac devices and we invoke the use in the early follow-up surveillance after endovascular repair of aortic aneurysm of noninvasive test such duplex scanning, segmental pressures and ankle-brachial indices to assess the presence or progress of coexistent occlusive disease. We also suggest that some adverse outcomes ascribed to device failure might be more properly charged to inappropriate patient selection.

KEY WORDS: Endovascular surgical procedures - Aortic aneurysm, abdominal - Aortouni-iliac graft.

Endovascular repair of aortic aneurysm has become a viable treatment option in selected patients. However, despite the minimally invasive nature of this treatment a significant incidence of vascular complications has been reported. One of the most frequent complications is graft thrombosis with an incidence in the series ranged from 0.6% to 9.9% (mean 5.1%)¹. Most of these cases represent endograft limb thrombosis of bifurcated devices and most cases of graft thrombosis were reported within the early postoperative period. Here, we report two cases of acute limb ischemia due to endograft thrombosis in patients

*Division of Vascular Surgery
University Clinic of Navarra, Pamplona, Spain*

treated with aortouni-iliac devices and we review the etiologic factors related with these events and the treatment options.

Case series

Case 1.—A Talent aorto-uni-iliac graft and a femoral crossover bypass graft with PTFE was used to treat an abdominal aortic aneurysm (AAA) in a 67 years old male patient. The patient had mild *claudication*, without popliteal and distal pulses and a bilateral ankle pressures <80 mmHg. The intraoperative angiography showed no technical defects and the good result were assessed before discharge with three-phase, contrast-enhanced computed tomography (CT) scan and plain abdominal radiograph. The patient was discharged 72 hours after the procedure and on postoperative day 14, the patient presented with bilateral acute lower limb ischemia with thrombosis of the femoral crossover bypass graft. CT scan reconstruction also showed thrombosis of the infrarenal aorta and the entire aortouni-iliac graft. The patient was treated with an axillofemoral bypass and thrombectomy of the femoro-femoral graft. At last follow-up, the patient died 13 months later due to a myocardial infarction and the graft remained patent.

Case 2.—A 76 years old man was referred to us with bilateral acute lower limb ischemia 15 days after treatment with a "custom-made" aortouni-iliac graft and femoral crossover bypass in other center. The CT scan reconstruction showed thrombosis of the infrarenal aorta, the aortouni-iliac and femoro-femoral grafts and the patient was treated with an axillofemoral bypass and thrombectomy of the femoro-femoral graft (Figure 1). At last follow-up, this graft remained patent 37 months after the procedure.

Address reprint requests to: L. Fernández-Alonso, Division of Vascular Surgery, Clinica Universitaria of Navarra, Avd. Pio XII 36, 31008 Pamplona, Spain. E-mail: lfezalonso@unav.es

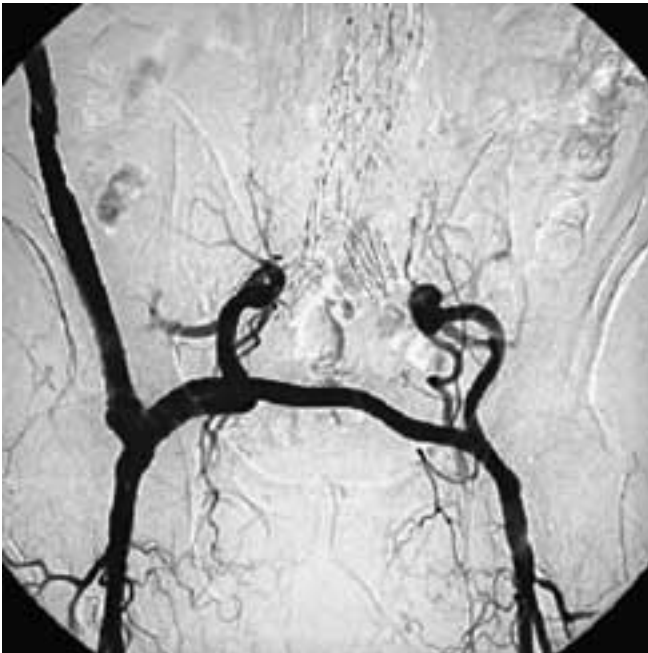


Figure 1. – Angiogram showing final result after revascularization in case 2. Note patency of both hypogastric arteries.

Discussion

Endograft thrombosis after endovascular repair of infrarenal AAA is a recognized complication²⁻⁴. In a recent literature review of endovascular aortic repair in which graft thrombosis was reported, the most common reported cause was stenosis of the iliac limb or limbs of the graft due to technical problems in graft deployment or placement¹. However, some other factors have been proposed to predispose to graft thrombosis including areas of stenosis, such as the aortic bifurcation and occlusive or iliac arteries,⁴ unsupported endograft devices,¹ irregularity of the endograft lumen from device overlap,⁵ stent graft material, changes in forces such as extrinsic compression from thrombus and changes in radial force from increasing luminal blood flow^{6,7} and arterial outflow⁸. Furthermore, in bifurcated grafts, Carroccio *et al.*⁸ identified a tendency for endograft limb thrombosis when the limb diameter was small and extended to the external iliac artery.

The bifurcated configuration has gained popularity in endovascular management of AAA because it appears more anatomic than the uni-iliac approach. However, bifurcated stent grafts are not suitable in all

patients and are more difficult and time-consuming to deploy. In fact, the use of bifurcated grafts are limited in many cases by complex iliac artery anatomy and specifically by an ectatic or frankly aneurysmal iliac, as well as iliac tortuosity or occlusive disease. In such circumstances, some iliac limitations of endovascular repair may be overcome with an aortouni-iliac device in conjunction with femorofemoral crossover bypass grafting when one iliac artery is suitable for access and device deployment. Recognized advantages to such a system include ease of device deployment, without rotational concerns, and no modular interface requirements and their potential pitfalls. Also, ease of use broadens endovascular repair of AAA applicability to patients with ruptured aneurysms⁹. Disadvantages unique to this repair include the potential drawbacks of femorofemoral bypass grafting, including poor late patency and infection, and development of thigh or buttock *claudication*. Further occasional difficulties with therapeutic contralateral iliac system occlusion may occur. However, several studies have confirmed the feasibility and mid-term success of placing such a repair configuration^{10,11} and this reconstruction option offers an effective treatment alternative in patients at high risk for open repair who have unilateral iliac artery anatomy unsuitable for bifurcated endografting¹⁰ and in ruptured aneurysms⁹.

The angiogram, three-phase, contrast-enhanced CT scan and plain abdominal radiograph before discharge showed good aneurysm exclusion with sac shrinkage and no endoleak, stenosis or kinking in our patients and there were no documented technical problems during the procedure. Both grafts in our patients were fully supported grafts and thrombosis occurs in both cases in the early postoperative period (up to 30 postoperative days).

We believe that the presence of atherosclerotic plaques within the outflow arteries and coexistent infrainguinal arterial occlusive disease (poor runoff) is an underestimated factor in the risk of graft thrombosis, especially in patients treated with aortouni-iliac devices, and we can speculate that our two patients had a poor inflow and a poor runoff that may be, at least in part, responsible of the early graft thrombosis. Our patient of case 1 have tortuosity of the external iliac arteries and severe stenotic disease in iliac and superficial femoral arteries (Figure 2) and our patient of case 2 have also severe occlusive disease of the superficial femoral arteries with mild claudication

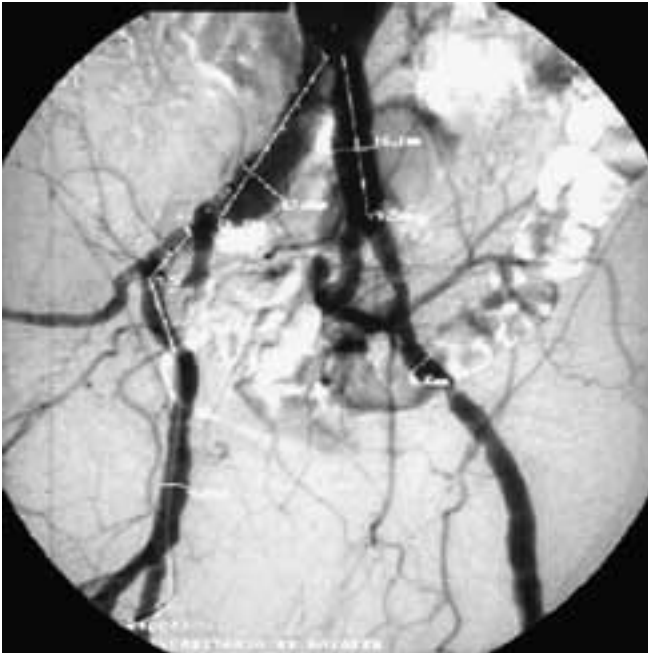

Figure 2. – Preoperative angiogram of case 1 showing tortuosity and stenotic disease of the iliac vessels.

and with a preoperative bilateral ankle/braquial <0.60 . Furthermore, our case 1 was associated with embolization of internal iliac artery and had aortouni-iliac grafts extended to the external iliac artery and, as speculate Carroccio *et al.*,⁸ the sacrifice of the hypogastric outflow can contribute to the detrimental of graft limb patency.

The quality and diameter of the femoral and iliac arteries are important factors and small diameters, tortuosity and arterial wall calcification may preclude delivery of the endograft. On the other hand, the presence of occlusive disease and tortuosity in the iliac arteries may result in graft diameters significantly more narrowed when compared with the measurements that were taken from preoperative angiograms and CT-scan. There is evidence to suggest that intravascular ultrasound (IVUS) is more effective than angiogram at confirming complete expansion of endograft and detecting residual stenosis of flow restricting lesions at increased risk for thrombosis¹². Aljabri *et al.*¹ suggest that the routine use of intraoperative IVUS in the setting of endovascular aneurysm repair may help to minimize the risk of postoperative graft limb thrombosis. Amesur *et al.*¹³ reported a greater ability of IVUS to identify narrowed limbs preoperatively and after the institution

of IVUS they improved dramatically the detection of stenosis and reported a rate of limb occlusion of 17% with the use of angiography alone and a rate of 0% with the use of IVUS at a mean follow-up of 14 months. We do not have any personal experience with IVUS.

Because most cases of graft thrombosis occurred within the early postoperative period (<30 days)¹ and are not related to endoleaks or aneurysm sac size we invoke the use in the early follow-up surveillance of non invasive test such duplex scanning, segmental pressures and ankle-braquial indices to assess the presence or progress of coexistent occlusive disease after the procedure.

When endograft thrombosis occurs the treatment options include conservative management, open surgical procedures and transfemoral endovascular procedures.

Conservative management with observation is an option of treatment in patients with symptoms of mild *claudication* but in patients with aortouni-iliac devices with entire occlusion of the graft is exceptional. As in our case 1, the loss of collateral flow from the hypogastric artery resulted in more progressive symptoms of ischemia and do not permit management with observation.

The open surgical procedures includes conversion to open repair or extraanatomic bypass and endovascular procedures includes balloon angioplasty and stenting and thrombolysis. In the large European collaborative registry (EUROSTAR) experience of more than 1000 patients followed for more than 12 months, 18% have needed secondary interventions after endovascular aneurysm repair including intervention for endograft thrombosis¹⁴. Twelve percent of secondary interventions were *via* the transabdominal approach, 11% were extra-anatomic bypass and 76% were transfemoral. Complete graft thrombosis was the indication for only one of the cases of transabdominal secondary intervention and limb occlusion was the most common indication for extra-anatomic revascularization. In the literature, most patients with limb or graft occlusions did not undergo thrombolysis and arteriography to help identify potential sources of thrombosis and underwent extra-anatomic bypass.

In our cases, both aortomonoiliac devices and both that one with acute thrombosis of the entire endograft resulting in severe lower extremity ischemia, emergent axilofemoral and thrombectomy of the femoro-

femoral graft was performed with a satisfactory result. According with Carroccio *et al.*⁸ we decided to manage the thrombosis with extra-anatomic bypass because of concerns that thrombectomy of the aortouni-iliac graft may have dislodged the graft. However, we performed thrombectomy of both iliac arteries distal to the endograft in order to achieve adequate flow in the hypogastric arteries. The good outcome of the extra-anatomic bypasses in our patients instead of the poor run off emphasize again the importance of anatomic criteria selection and the importance of the maintenance of a good inflow in the femoral crossover bypass graft when an aortomonoiliac device is used.

Our two cases emphasize the importance of proper and appropriate patient selection and adherence to anatomic selection criteria and suggest that some adverse outcomes ascribed to device failure might be more properly charged to inappropriate patient selection.

Conclusions

We believe that the presence of atherosclerotic plaques within the outflow arteries and coexistent infrainguinal arterial occlusive disease (poor runoff) is an underestimated factor in the risk of graft thrombosis, especially in patients treated with aortouni-iliac devices, and we invoke the use in the early follow-up surveillance after endovascular repair of aortic aneurysm of non invasive test such duplex scanning, segmental pressures and ankle-brachial indices to assess the presence or progress of coexistent occlusive disease.

Our two cases emphasize again the importance of proper and appropriate patient selection and adherence to anatomic selection criteria and suggest that some adverse outcomes ascribed to device failure might be more properly charged to inappropriate patient selection. Moreover, when thromboses occurred, intervention is successful in reestablishing arterial perfusion and relieving ischemic symptoms even in the long term follow-up.

References

1. Aljabri B, Obrand DI, Montreuil B, MacKenzie KS, Steinmetz OK. Early vascular complications after endovascular repair of aortoiliac aneurysms. *Ann Vasc Surg* 2001;15:608-14.
2. Baum RA, Shetty SK, Carpenter JP, Soulen MC, Velazquez OC, Shlansky-Goldberg RD *et al.* Limb kinking in supported and unsupported abdominal aortic stent-grafts. *J Vasc Interv Radiol* 2000;11:1165-71.
3. Ohki T, Veith FJ, Shaw P, Lipsitz E, Suggs WD, Wain RA *et al.* Increasing incidence of midterm and long-term complications after endovascular graft repair of abdominal aortic aneurysms: a note of caution based on a 9-year experience. *Ann Surg* 2001;234:323-34.
4. Carpenter JP, Neschis DG, Fairman RM, Barker CF, Golden MA, Velazquez OC *et al.* Failure of endovascular abdominal aortic aneurysm graft limbs. *J Vasc Surg* 2001;33:296-303.
5. Becquemin JP, Lapie V, Favre JP, Rousseau H. Mid-term results of second generation bifurcated endovascular graft for abdominal aortic aneurysm repair: the French vanguard trial. *J Vasc Surg* 1999;30:209-18.
6. Chuter TA, Wendt G, Hopkinson BR, Scott RA, Risberg B, Kieffer E *et al.* European experience with a system for bifurcated stent-graft insertion. *J Endovasc Surg* 1997;4:13-22.
7. Silberzweig JE, Marin ML, Hollier LH, Mitty HA, Parsons RE, Cooper JM *et al.* Aortoiliac aneurysms: endoluminal repair-clinical evidence for a fully supported stent-graft. *Radiology* 1998;209:111-6.
8. Carroccio A, Faries PL, Morrissey NJ, Teodorescu V, Burks JA, Graveriaux EC *et al.* Predicting iliac limb occlusions after bifurcated aortic stent grafting: Anatomic and device-related causes. *J Vasc Surg* 2002;36:679-84.
9. Veith F, Ohki T, Lipsitz EC, Suggs WD, Cynamon J. Endovascular grafts and other catheter-directed techniques in the management of ruptured abdominal aortic aneurysms. *Semin Vasc Surg* 2003;16:326-31.
10. Clouse DW, Brewster DC, Marone LK, Cambria RP, LaMuraglia GM, Watkins MT *et al.* Durability of aortouniiliac endografting with femorofemoral crossover: 4-years experience in the EVT/ Guidant trials. *J Vasc Surg* 2003;37:1142-9.
11. Hinchliffe RJ, Alric P, Wenham PW, Hopkinson BR. Durability of femorofemoral bypass grafting after aortouniiliac endovascular aneurysm repair. *J Vasc Surg* 2003;38:498-503.
12. Arko F, Mettauer M, McColloug R, Patterson D, Manning L, Lee S *et al.* Use of intravascular ultrasound improves long-term clinical outcome in the endovascular management of atherosclerotic aortoiliac occlusive disease. *J Vasc Surg* 1998;27:614-23.
13. Amesur NB, Zajko AB, Orons PD, Makaroun MS. Endovascular treatment of iliac limb stenoses or occlusions in 31 patients treated with the ancure endograft. *J Vasc Interv Radiol* 2000;11:421-8.
14. Laheij RJ, Buth J, Harris PL, Moll FL, Stelter WJ, Verhoeven EL. Need for secondary interventions after endovascular repair of abdominal aortic aneurysms. Intermediate-term follow-up results of a European collaborative registry (EUROSTAR). *Br J Surg* 2000;87:1666-73.