

A case of labyrinthitis diagnosed with MRI

Saiz-Mendiguren R, García-Lallana A, Simon I, Slon P, Etxano J, Dominguez PD, Zubieta JL, García-Eulate R.

Radiology Service. Clínica Universidad de Navarra, Pamplona, Spain.
Clinica Universidad de Navarra

CLINICAL HISTORY

A 91 year old woman was evaluated for a past history of colon cancer. She complained of hearing loss and episodes of persistent tinnitus followed by rotatory vertigo. She was referred to the radiology department for an abdominal ultrasound, a thoracic CT and a brain MRI.

IMAGING FINDINGS

A 91 year old woman who complained of hearing loss and episodes of persistent tinnitus followed by rotatory vertigo was referred to our radiology department for a brain MRI. She had a previous medical history of cholecystectomy and colon cancer surgically treated (hemicolectomy). Abdominal US and thoracic CT were strictly normal.

Brain MRI showed frontotemporal atrophy, leukoaraiosis and a right sided frontal meningioma. In the 3D-CISS T2 sequence the left membranous labyrinth was not correctly appreciated (Fig 1), when studied in the post-gadolinium T1 sequence the left labyrinth enhances significantly (Fig 2, 3) and in the T2 FLAIR sequence it is significantly brighter than the right labyrinth (Fig 4). These findings associated with the clinical symptoms were suggestive of a labyrinthitis.

DISCUSSION

Nowadays, labyrinthitis is a rare complication of otitis media. Its incidence has declined due to an earlier diagnosis and new antibiotics treatments.

The differentiation between serous and suppurative labyrinthitis is clinical, and it may be difficult in the acute phase. Acute serous labyrinthitis is caused by irritation to the labyrinth by otitis media or meningitic infection, without bacterial invasion of the inner ear. The irritation of the labyrinth is induced by bacterial toxins or other mediators of inflammation. Suppurative labyrinthitis is the result of direct bacterial invasion and may cause vertigo and irreversible hearing loss [1].

MRI is a helpful technique to confirm the presence of labyrinth inflammation. Although segmental involvement of the labyrinth is not uncommon, typical findings are faint and

diffuse enhancement of the membranous labyrinth on gadolinium T1-weighted sequences. Labyrinthine enhancement usually occurs in the subacute phase. Differential diagnosis must be done with intralabyrinthine schwannoma, which is segmental and heavily enhancing and with intralabyrinthine haemorrhage, which is hyperintense on non-gadolinium T1 WI [2-4].

It is believed that a breakdown of labyrinthine vasculature permits the accumulation of gadolinium within inflamed labyrinthine membranes, which is the cause of the labyrinth enhancement on gadolinium T1 weighted images [4].

Treatment of labyrinthitis caused by otitis media is middle ear drainage and antibiotic therapy. If hearing loss is persistent after treatment the next step should be steroid therapy, which improves the reduction of hearing loss. Other treatments such as myringotomy and ventilation tube insertion might be reserved for patients with serous labyrinthitis associated with otitis media. [5]

If serous labyrinthitis is not treated it can cause suppurative labyrinthitis and even meningitis.

FINAL DIAGNOSIS

Labyrinthitis

DIFFERENTIAL DIAGNOSIS LIST

Labyrinthitis, Intralabyrinthine schwannoma, Intralabyrinthine hemorrhage

REFERENCES

- [1] Jang CH, Park SY, Wang PC (2005) A Case of Tympanogenic Labyrinthitis Complicated by Acute Otitis Media *Yonsei Medical Journal* 46(1):161-5
- [2] Dubrulle F, Kohler R, Vincent C, Puech P, Ernst O (2010) Differential diagnosis and prognosis of T1-weighted post-gadolinium intralabyrinthine hyperintensities *Eur Radiol* 20(11):2628-36
- [3] Mafee MF (1995) MR imaging of intralabyrinthine schwannoma, labyrinthitis and other labyrinthine pathology *Otolaryngol Clin North Am* 28(3):407-30
- [4] Seltzer S, Mark AS (1991) Contrast enhancement of the labyrinth on MR scans in patients with sudden hearing loss and vertigo: evidence of labyrinthine disease *Am J Neuroradiol* 12(1):13-6
- [5] Rappaport JM, Bhatt SM, Burkard RF, Merchant SN, Nadol JB Jr (1999) Prevention of hearing loss in experimental pneumococcal meningitis by administration of dexamethasone and ketorolac *J Infect Dis* 179(3):753

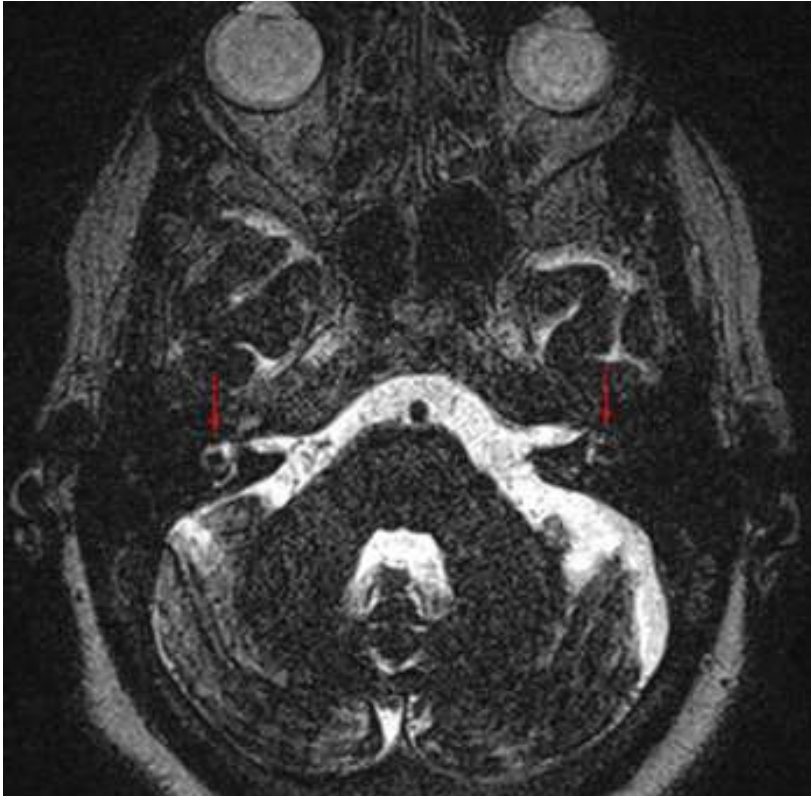

Figure 1. 3D-CISS T2 Weighted image

3D-CISS T2 WI. In this image it is noticed that the left labyrinth is less brighter than the right one.

Area of Interest: Head and neck.

Imaging Technique: MR.

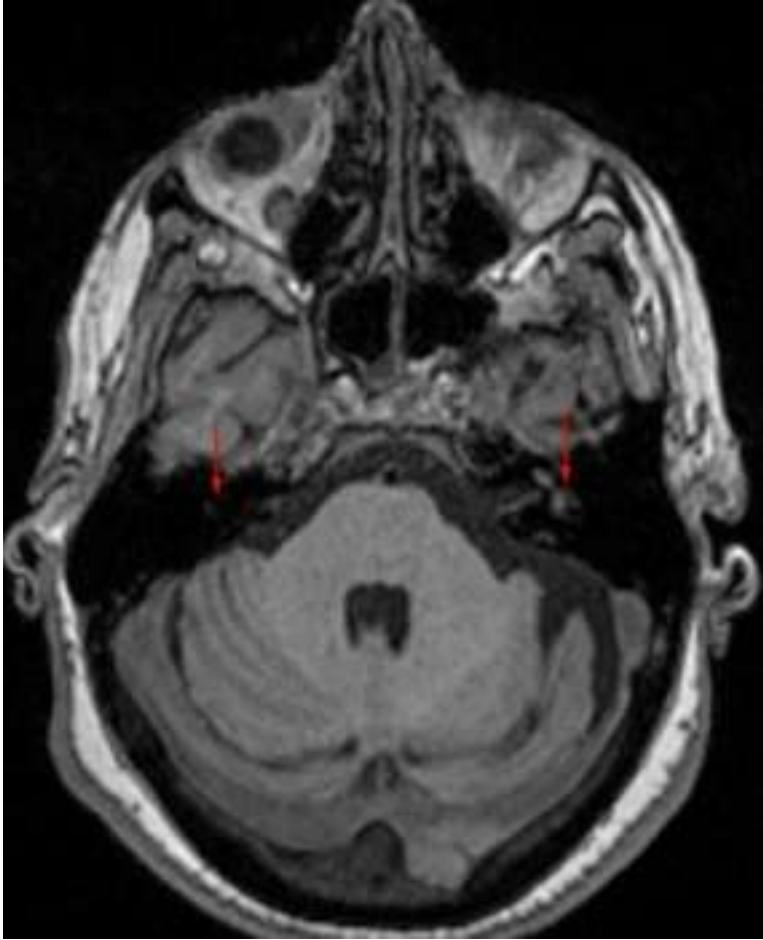


Figure 2. T1 Weighted Image

In this T1 non gadolinium enhanced image it can be seen that both the left and the right labyrinth have a normal intensity.

Area of Interest: Head and neck.

Imaging Technique: MR.

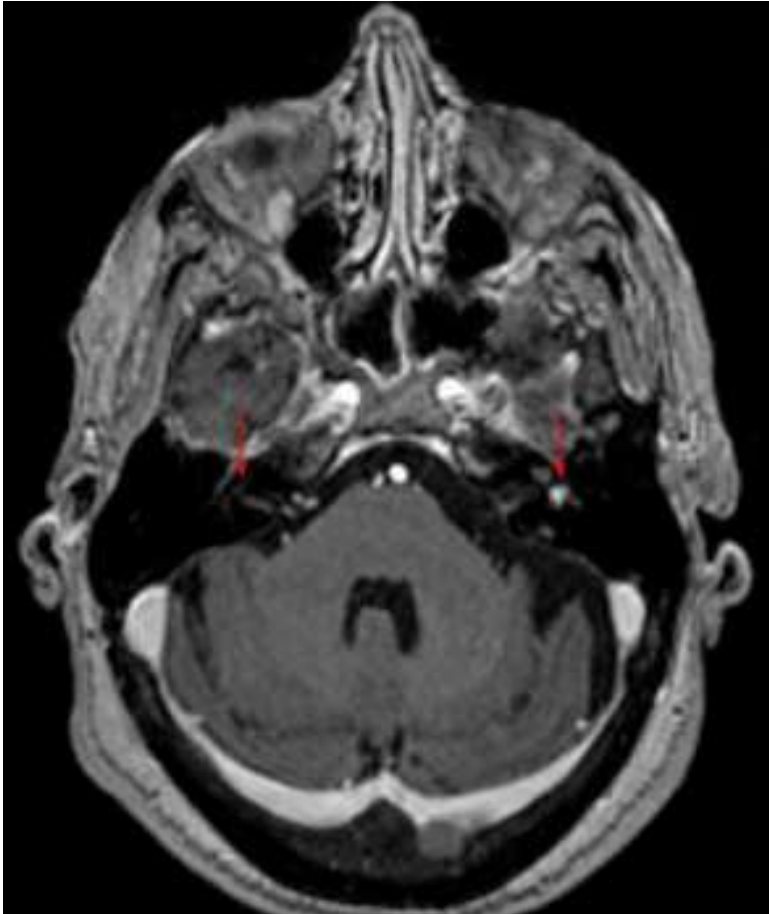


Figure 3. T1 Gadolinium enhanced Weigthed Image

T1 Gadolinium enhanced image in the showing the same structures that figure 2. Left labyrinth diffuse enhancement can be observed.

Area of Interest: Head and neck.

Imaging Technique: MR.

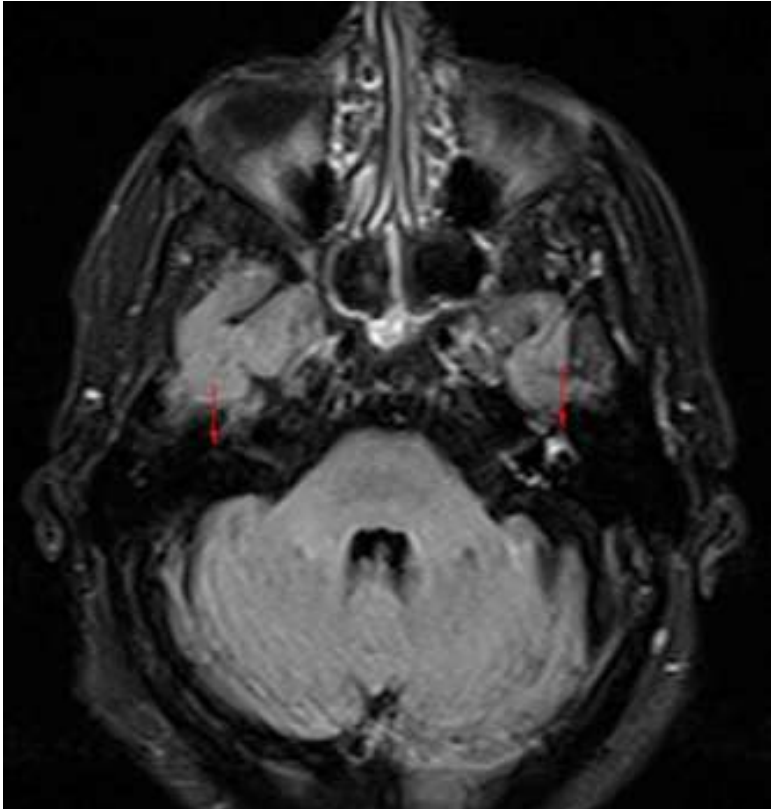


Figure 4. T2 FLAIR Weighed Image

In this image the left labyrinth is brighter than the right one, this indicates that the endolymph in the left labyrinth has a high content in proteins (infection, hematogenous content).

Area of Interest: Head and neck.

Imaging Technique: MR.