

Images in medicine

Pneumatocele formation following COVID-19 pneumonia

FORMACIÓN DE NEUMATOCELE TRAS NEUMONÍA POR COVID-19

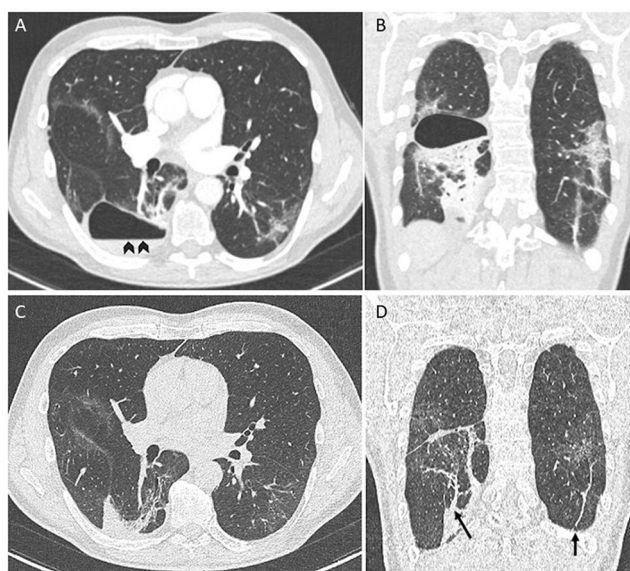
Miguel Sogbe^{a,b}, I. Madeleine Di Frisco^c, Ana Ezponda^d y José Luis del Pozo^{a,e,f,*}^a Infectious Diseases Division, Clínica Universidad de Navarra, Pamplona, Spain^b Internal Medicine Department, Clínica Universidad de Navarra, Pamplona, Spain^c Pulmonary Medicine Department, Clínica Universidad de Navarra, Pamplona, Spain^d Radiology Department, Clínica Universidad de Navarra, Pamplona, Spain^e IdiSNA, Navarra Institute for Health Research, Pamplona, Spain^f Microbiology Department, Clínica Universidad de Navarra, Pamplona, Spain

Fig. 1. Chest Angio-CT. Thin-walled cystic lesion with an air-fluid level (arrowheads) (A) and consolidations in lower lobes (B). Chest Angio-CT performed eight weeks later showed complete resolution of the pneumatocele (C) with persisting subpleural and parenchymal bands (arrows) (D).

A 61-year-old man with no significant medical history presented to the emergency department with worsening dyspnea a week after close contact with someone who had COVID-19. He was unvaccinated. He was hypoxemic, and the chest radiograph showed bilateral opacities consistent with COVID-19 pneumonia and tested positive for RNA from SARS-CoV-2. Blood tests showed raised inflammatory markers. Computed tomography (CT) of the chest demonstrated bilateral ground-glass opacities. The patient was hospitalized and treated with high-flow nasal oxygen therapy, dexamethasone, and sarilumab. His clinical status improved, and he was discharged home after 1 week of hospitalization. Three weeks later, he presented again with worsening dyspnea, fever, and pleuritic chest pain. A CT pulmonary angiography ruled out pulmonary embolism (Fig. 1A, B) but demonstrated a thin-walled cystic lesion with an air-fluid level (Fig. 1A, arrowheads) that suggested an infected pneumatocele. The patient was managed conservatively with amoxicillin/clavulanic acid for 3 weeks. During the follow-up, the patient reported the disappearance of symptomatology. A subsequent

* Corresponding author at: Infectious Diseases Division, Clínica Universidad de Navarra, Avda. Pio XII 36, 31008 Pamplona, Spain.
E-mail address: jdelpozo@unav.es (J.L. del Pozo).

CT performed 8 weeks after the diagnosis showed complete resolution of the pneumatocele (Fig. 1C, D) with persisting subpleural and parenchymal bands (Fig. 1D, arrows).

Funding

None.

Potential conflicts of interest

J.P. has been a consultant for Pfizer, MSD, Gilead, and Novartis. Other authors: No reported conflicts.

Acknowledgments

None