

**SHORT REPORT****Alpelisib decreases nevocytes of congenital melanocytic nevi**

Alejandra Tomás-Velázquez<sup>1</sup>  | Juan Carlos López-Gutiérrez<sup>2</sup> | Carlos de Andrea<sup>3</sup> | Miguel Reyes-Múgica<sup>4</sup> | Claudia M. Salgado<sup>4</sup> | Pedro Redondo<sup>1</sup> 

<sup>1</sup>Department of Dermatology, University Clinic of Navarra, Madrid, Spain

<sup>2</sup>Department of Pediatric Surgery, Hospital La Paz, Madrid, Spain

<sup>3</sup>Department of Pathology, University Clinic of Navarra, Pamplona, Spain

<sup>4</sup>Department of Pathology, UPMC Children's Hospital of Pittsburgh, Pittsburgh, Pennsylvania, USA

**Correspondence**

Alejandra Tomás-Velázquez, Department of Dermatology, University Clinic of Navarra, Marquesado de Sta. Marta, 1, Madrid 28027, Spain.

Email: [atomasv@unav.es](mailto:atomasv@unav.es)

**Funding information**

Instituto de Salud Carlos III

**Abstract**

**Background:** Multiple, large or giant congenital melanocytic nevi (CMN) are uncommon and affected patients can show progressive growth and thickening, associate neurocutaneous melanocytosis or develop melanoma. Current treatment modalities are mostly complex surgeries that frequently do not solve the disease and its risks completely. Thus, investigation on new treatment options for CMN and its complications must continue. MAPK pathway inhibitors are being investigated, also targeting PI3K-AKT. Omipalisib (PI3K inhibitor, with no indications approved yet) has been studied for CMN in vitro and in mice with promising results. However, alpelisib, a PI3K inhibitor approved with an adequate safety profile for patients with severe manifestations of PROS (PIK3CA-Related Overgrowth Spectrum), had not yet been tested for CMN.

**Objective:** To evaluate the effect of alpelisib in nevocytes of congenital melanocytic nevi.

**Methods:** Nevomelanocytic tissue samples of 10 patients were collected prospectively and, following a previously reported preclinical ex vivo model, explants were placed in organotypic culture for 5 days, with or without alpelisib. Consecutively, tissue sections were stained and using scanned images with Qupath and ImageJ softwares, representative regions from the dermis were analysed (using Wilcoxon test and Spearman's correlation).

**Results:** When comparing alpelisib-treated explants with respect to control explants, we found a decrease in cell density ( $p = 0.0273$ ), in density of SOX10<sup>+</sup>-cells ( $p = 0.0391$ ) and also in the % of S-100<sup>+</sup> area ( $p = 0.0078$ ), in alpelisib samples. The three markers showed a positive correlation ( $p < 0.05$ ).

**Conclusions:** This study provides first-time evidence that alpelisib induces nevocyte reduction in CMN from patient-derived explants, probably induced by autophagy. Alpelisib is an approved drug with an adequate safety profile used in another mosaicism affecting PI3K (PROS). Further studies are needed to evaluate its efficacy in treating CMN and potentially, their complications, either with local or systemic administration, alone or in combination.

**INTRODUCTION**

Multiple/large/giant congenital melanocytic nevi (>20 cm PAS; gCMN)<sup>1</sup> are uncommon, and affected patients can show progressive growth, thickening,<sup>2</sup> associate with neurocutaneous melanocytosis (NCM)<sup>3</sup> or develop melanoma.<sup>4</sup>

Current treatment modalities are mostly surgical. In some patients, NCM can progress, become symptomatic or develop malignant transformation ('malignant melanoma') in the central nervous system or skin, leading to death in many cases. Thus, investigation on new treatment options for CMN and its complications must continue.

This is an open access article under the terms of the [Creative Commons Attribution-NonCommercial-NoDerivs](https://creativecommons.org/licenses/by-nc-nd/4.0/) License, which permits use and distribution in any medium, provided the original work is properly cited, the use is non-commercial and no modifications or adaptations are made.

© 2023 The Authors. *Journal of the European Academy of Dermatology and Venereology* published by John Wiley & Sons Ltd on behalf of European Academy of Dermatology and Venereology.

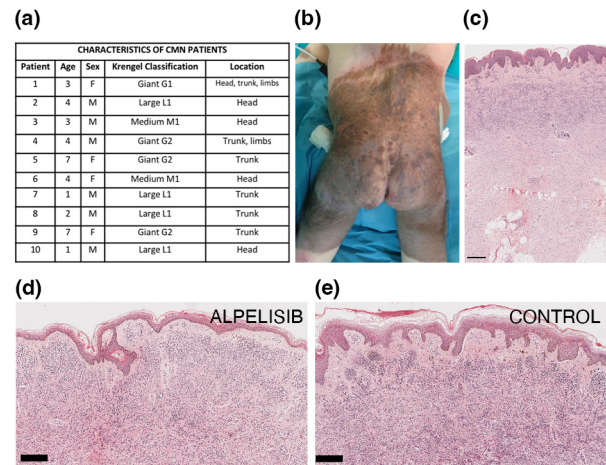
Most CMN harbour mutations of NRAS, and some of BRAF<sup>5-7</sup> causing a dysregulation of the microtubule-associated protein kinase (MAPK) signal transduction pathway leading to increased cell survival and proliferation.<sup>8</sup> Downstream signalling includes multiple protein kinases (MAPK, MEK-ERK, PI3K-AKT, etc.) and complex melanocyte precursor proliferation and differentiation steps, which may represent therapeutic targets. MAPK pathway inhibitors are being investigated in vitro, with a few clinical cases described.<sup>2,9</sup> Recently, promising results of locally delivered MEK, PI3K and c-KIT inhibitors were reported in mice.<sup>10</sup> Treatments based on other mechanisms are also being studied with interesting results, such as SADBE (squaric acid dibutyl ester-based immunotherapy)<sup>10</sup> or Vorinostat (a histone deacetylase inhibitor).<sup>11</sup>

The anti-tumour activity of targeting PI3K-AKT proteins is widely demonstrated. In fact, alpelisib (a phosphatidylinositol 3-kinase inhibitor which works by selectively inhibiting class I PI3K p110 $\alpha$ ) is approved and used in clinical practice in breast cancer<sup>12</sup>; and the FDA also granted an accelerated approval for patients with severe manifestations of PROS (PIK3CA-Related Overgrowth Spectrum), as they were orphaned of treatment thus far. However, while omipalisib (which dually targets direct phosphorylation of Akt by PI3Kinase and reverse phosphorylation by mTOR), with no indications approved yet, has been studied for CMN in vitro and in mice,<sup>10,13</sup> we were not able to find any studies with alpelisib, an approved drug with a known adequate safety profile.

The aim of our study was to assess the effect of alpelisib in CMN in a previously reported preclinical ex vivo model of CMN explants.

## METHODS

Ten consecutive patients who were to undergo surgical treatment (Figure 1) were included. Clinical data and nevomelanocytic tissue samples were prospectively collected after all patients provided written informed consent. CMN samples were obtained by performing 8 mm skin punch biopsies from the most representative and homogeneous area of the lesions. Following a previously reported preclinical ex vivo model,<sup>9</sup> explants were placed in organotypic culture for 5 days in DMEM/F12 supplemented with epidermal growth factor (100 ng/mL), basic fibroblast growth factor (100 ng/mL), 10% decomplemented foetal calf serum and insulin (5  $\mu$ g/mL). Explants were cultured with alpelisib 25  $\mu$ M (BYL719) or without alpelisib (control samples). After 5 days of incubation, explants were harvested, washed with phosphate buffered saline, fixed in formalin and embedded in paraffin (FFPE). Tissue sections were routinely stained with haematoxylin and eosin and processed for immunohistochemistry (IHC) and for 4-plex immunofluorescence (IF). IHC staining for S100 protein was performed using standard protocols, following the manufacturer's instructions. A 4-plex colour multiplexed quantitative immunofluorescence



**FIGURE 1** Patients characteristics, clinical image of one patient and pathological images of haematoxylin-eosin (H&E) of a giant CMN (case 4). (a) Table with demographic and CMN characteristics of patients included in the study. (b) Patient with a giant CMN with *bathing-trunk* pattern (case 4). (c) H&E of original gCMN tissue specimen (case 4). (d) H&E of day 5 CMN explants cultured with alpelisib (case 4). (e) H&E of day 5 CMN explants cultured without alpelisib (vehicle, control) (case 4). Scale bar: 250  $\mu$ m.

protocol for FFPE tissue sections was used for simultaneous detection of SOX10, cleaved-caspase-3, Ki67 and DAPI. Multiplexed IF assay development and validation have been previously described by our group.<sup>14</sup> IHC slides were scanned with an Aperio CS2 slide scanner (Leica Biosystems, Buffalo Grove, IL, USA). 4-plex immunofluorescence were scanned on a PhenoImager HT Automated Quantitative Pathology Imaging System (Akoya Biosciences). Each digital whole-slide image was preprocessed as describe before.<sup>15</sup> Image analysis was then performed using the open-source digital pathology software QuPath version 0.2.3 (University of Edinburgh, Edinburgh, UK; <https://qupath.github.io>) and ImageJ software version 1.52c (NIH, Bethesda, MD, USA; <https://imagej.nih.gov/ij>). Briefly, to allow all samples to be comparable, two representative regions (0.25mm<sup>2</sup> each) from the dermis from each sample (CMN avoiding appendages) were studied. Based on the intensity of each marker, cells were further classified as SOX10+ cells, the S-100+, Ki-67+ cells and cleaved-caspase-3+ cells. DAPI+ cells were used to calculate the total number of cells. Additionally, the area of S-100 positive staining was measured by pixel intensity.

We compared variables between treatment (alpelisib) and control using Wilcoxon-signed-rank-test; and we studied the correlation between the decreases in SOX10 or S100 variables and the cell density variation using Spearman's correlation (STATA/SE v16.0, two-tailed-tests,  $p$ -values<0.05 considered statistically significant).

## RESULTS

When comparing alpelisib-treated explants (ATE) with control explants (CE), cell density was significantly lower in




ATE (median: 6142 cells/mm<sup>2</sup> IQR: 3846–6194 VS CE median: 7399 cells/mm<sup>2</sup> IQR: 6128–7634;  $p=0.0273$ ). Although cell density was studied by IF and image analysis software as indicated above, changes in haematoxylin and eosin samples were also evidenced and a detail of a case is shown in Figure 1.

Immunofluorescent staining revealed a significant decrease in density of SOX10<sup>+</sup>-cells in the dermis of explants cultured with 25 μM alpelisib (Figure 2, ATE median: 2192 cells/mm<sup>2</sup> IQR: 1294–2492 VS CE median: 2662 cells/mm<sup>2</sup> IQR: 2420–3046;  $p=0.0391$ ).

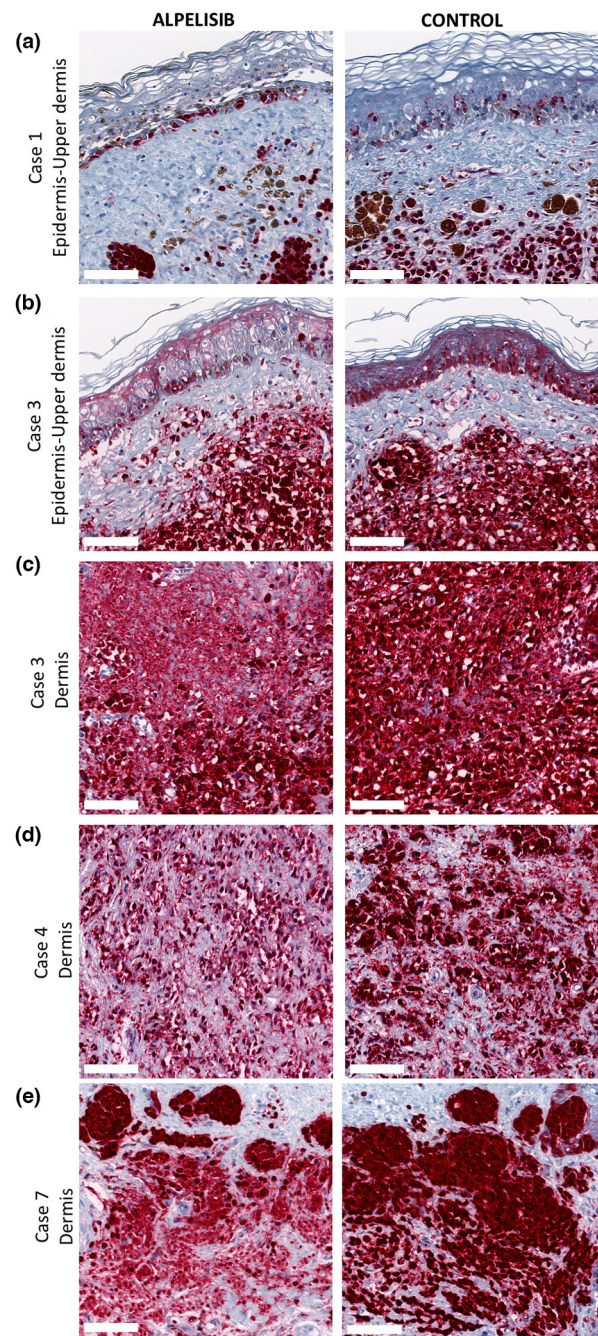
Regarding % of S-100<sup>+</sup> area, it was also significantly decreased in ATE (Figure 3, median: 23.16% IQR: 12.76–45.11 VS CE median: 39% IQR: 32.27–52.63;  $p=0.0078$ ).

No differences were found in density of cleaved-caspase-3<sup>+</sup>-cells (ATE median: 72 cells/mm<sup>2</sup> IQR: 56–78 VS CE median: 55 cells/mm<sup>2</sup> IQR: 28–140;  $p=0.35$ ) and density of Ki-67<sup>+</sup>-cells (ATE median: 6 cells/mm<sup>2</sup> IQR: 2–16 VS CE median: 11 cells/mm<sup>2</sup> IQR: 0–16;  $p=0.98$ ).

Decreases in density of SOX10<sup>+</sup>-cells and % of S-100<sup>+</sup> area showed a significantly positive correlation with cell density



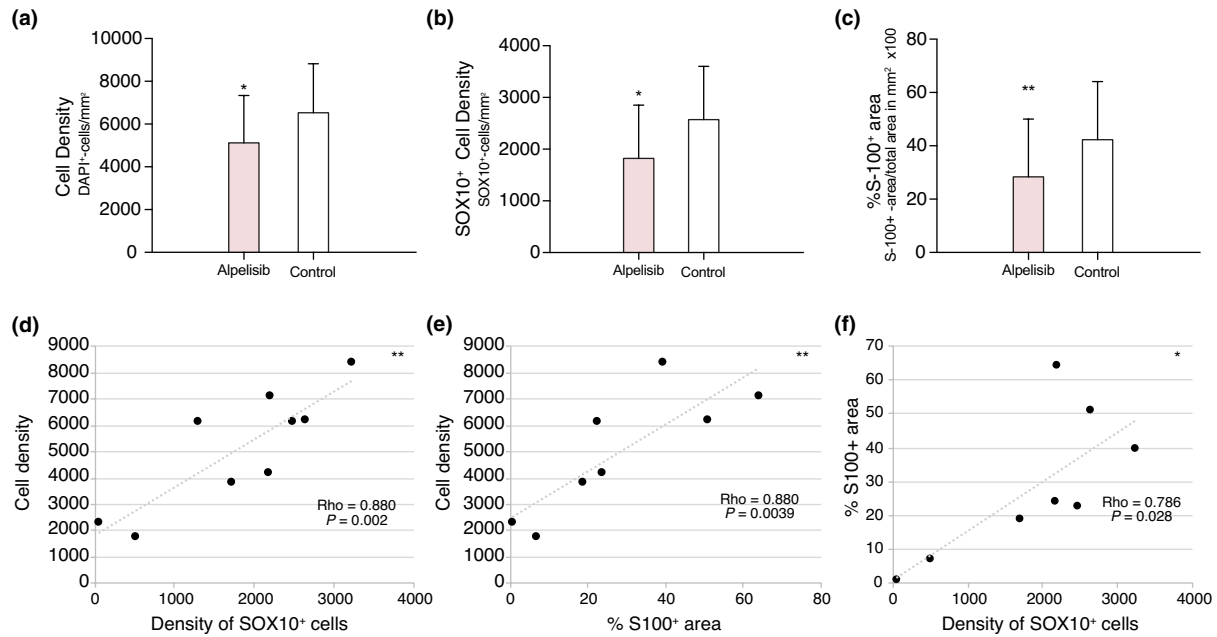
**FIGURE 2** Immunofluorescent stainings showing alpelisib alterations on CMN's nevocytes population in contrast with controls. (a–c) Details of immunofluorescent staining of the dermis of three CMN explants cultured with (left) and without (right) alpelisib. Note the decrease in cell density (DAPI<sup>+</sup> cells, in blue) and SOX10<sup>+</sup> cells (in green) in explants exposed to alpelisib (left). Scale bar: 75 μm.



**FIGURE 3** S100 stainings showing alpelisib alterations on CMN's nevocytes population in contrast with controls. (a and b) Details of S100 stain of the epidermis and upper dermis of two CMN explants cultured with (left) and without (right) alpelisib. Note the epidermal changes in explants exposed to alpelisib. (c–e) Details of S100 stain of the dermis of three CMN explants cultured with (left) and without (right) alpelisib. Note the decrease in S-100<sup>+</sup> area in explants exposed to alpelisib (left).

reduction ( $Rho=0.88$ ;  $p=0.0016$  and  $Rho=0.88$   $p=0.0039$ , respectively), and density of SOX10<sup>+</sup>-cells and % of S-100<sup>+</sup> area showed a significantly positive correlation between them ( $Rho=0.7857$ ;  $p=0.028$ ).

Results summarized in Figure 4.



**FIGURE 4** PI3K inhibition with alpelisib decreases nevocyte number in CMN explants. (a–c) Histograms show cell density (a, DAPI<sup>+</sup> cells/mm<sup>2</sup>), density of SOX10<sup>+</sup> (b, SOX10<sup>+</sup> cells/mm<sup>2</sup>) and % of S-100<sup>+</sup> area (c, S-100<sup>+</sup> area/total area studied in mm<sup>2</sup>, ×100) in alpelisib VS control explants. (d–f) Positive and significant associations between decrease in cell density and density of SOX10<sup>+</sup> cells (d) and %S100<sup>+</sup> area (e); and between both markers (f), respectively. \* $p < 0.05$ , \*\* $p < 0.01$ .

## DISCUSSION

This study provides first-time evidence that alpelisib induces nevocyte reduction in CMN from patient-derived explants. A potential mechanism behind this is autophagy, as previously reported by Basu *et al.* using omipalisib (a drug with similar mechanism of action).<sup>13</sup> Apoptosis does not seem to play a role in this reduction, as no differences for caspase-3 expression were found between treated and untreated explants. In addition, proliferating cells (Ki-67 positive) were rarely seen on treated and untreated samples. It has been also demonstrated that PI3K inhibition prevents colony formation by affecting clonogenic growth of NCM cells in vitro.<sup>13</sup>

Phosphoinositide 3-kinases (PI3Ks) is a well-characterized RAS effector family which play important roles as mediators of RAS-mediated cellular growth, transformation, adhesion, apoptosis, survival and motility. Activation of PI3K can occur by at least 3 independent pathways starting with binding of a ligand to receptor tyrosine kinases, one of which is via RAS.<sup>16</sup> In fact, it has been shown that PI3K signalling is indispensable to maintain transformed growth in RAS mutant cell lines both in vitro and in xenografts in mice.<sup>17</sup> The PI3K family of enzymes is organized into three main classes (class I, II and III), and various subgroups. The catalytic subunits for the class I PI3Ks are p110 $\alpha$ , p110 $\beta$ , p110 $\gamma$  and p110 $\delta$ . Alpelisib works by selectively inhibiting class I PI3K p110 $\alpha$ . For years, it is known the role of class I PI3K p110 $\alpha$  for oncogenic growth.<sup>18</sup>

Regarding treatment of the CMN, we find a benign condition with different possible phenotypes that can affect

each patient in variable ways for which to date only surgery is available. There are CMNs that show progressive growth and thickening, others remain stable and some, occasionally, although infrequent, even regress. In particular, those CMNs that present progressive growth may be associated with pain, pruritus or disfigurement, leading to social isolation or difficulties in daily living (hygiene), all important complications to prevent. For those patients, current options are limited to surgery and medical management of associated symptoms. As no effective pharmacologic treatments are available for these situations, isolated cases have been reported using systemic drugs (as trametinib).<sup>2</sup> In these cases, a specific topical treatment would be very useful, even if just lesion's stabilization and improvement of the symptoms would be achieved.

Recently, it has been reported that local administration of MEK inhibitors and omipalisib (PI3K inhibitor) resulted in depigmentation and loss of melanocytes in mice.<sup>10</sup> Along this line, developing trials in CMN patients for alpelisib, either alone or in combination, may prove useful in topical and/or systemic treatments.

As mentioned above, alpelisib is used in clinical practice in children suffering other mosaicism affecting PI3K pathway (PROS) with an appropriate safety profile and associated with clinical improvements. Firstly, its efficacy was demonstrated in mouse models and some case reports, some patients received the treatment for compassionate use under a managed access program<sup>19</sup> and currently, a randomized controlled study is ongoing (EPIK P2-NCT04589650).

By other hand, children affected by advanced malignant transformation or progressive NCM have no effective



treatments so far. We have neither tested alpelisib in these situations, nor found any comparable study; therefore, no evidence-based conclusions can be drawn. However, most malignant progressions in CMN are thought to be NRAS mutated<sup>4</sup> and Posch et al.<sup>20</sup> found that while NRAS mutant cells were more sensitive to MEK inhibition, when inhibiting MEK, PI3K signalling was more important for cell survival. Thus, combined targeting achieves synergic activity. Alpelisib (probably in combination) may be tested for CMN complications.

In conclusion, we show evidence supporting that alpelisib could be useful in the treatment of children with CMN, which warrants further study.

## ACKNOWLEDGEMENTS

We are grateful to our patients and relatives for their cooperation and kindness and to all the colleagues who helped us with the study.

## FUNDING INFORMATION

The research has been partially funded by grants from Instituto de Salud Carlos III, from Spain. The funders had no role in the design and conduct of the study; in the collection, analysis and interpretation of the data; in the decision of the submission of the manuscript; or in the preparation, review or approval of the manuscript.

## CONFLICT OF INTEREST STATEMENT

The authors have no conflict of interest to declare.

## DATA AVAILABILITY STATEMENT

The data that support the findings of this study are available from the corresponding author upon reasonable request.

## ETHICS STATEMENT

No identifiable patient photographs or other identifiable material are included in the present article. Informed consent was obtained by the authors from all patients.

## ORCID

Alejandra Tomás-Velázquez  <https://orcid.org/0000-0002-9216-4461>

Pedro Redondo  <https://orcid.org/0000-0001-7899-2511>

## REFERENCES

- Krengel S, Scope A, Dusza SW, Vonthein R, Marghoob AA. New recommendations for the categorization of cutaneous features of congenital melanocytic nevi. *J Am Acad Dermatol*. 2013;68(3):441–51.
- Mir A, Agim NG, Kane AA, Josephs SC, Park JY, Ludwig K. Giant congenital melanocytic nevus treated with trametinib. *Pediatrics*. 2019;143(3):e20182469.
- Kadonaga JN, Frieden IJ. Neurocutaneous melanosis: definition and review of the literature. *J Am Acad Dermatol*. 1991;24(5 Pt 1):747–55.
- Kinsler VA, O'Hare P, Bulstrode N, Calonje JE, Chong WK, Hargrave D, et al. Melanoma in congenital melanocytic naevi. *Br J Dermatol*. 2017;176(5):1131–43.
- Charbel C, Fontaine RH, Malouf GG, Picard A, Kadlub N, El-Murr N, et al. NRAS mutation is the sole recurrent somatic mutation in large congenital melanocytic nevi. *J Invest Dermatol*. 2014;134(4):1067–74.
- Salgado CM, Basu D, Nikiforova M, Bauer BS, Johnson D, Rundell V, et al. BRAF mutations are also associated with neurocutaneous melanocytosis and large/giant congenital melanocytic nevi. *Pediatr Dev Pathol*. 2015;18(1):1–9.
- Martins da Silva V, Martinez-Barrios E, Tell-Martí G, Dabad M, Carrera C, Aguilera P, et al. Genetic abnormalities in large to Giant congenital nevi: beyond NRAS mutations. *J Invest Dermatol*. 2019;139(4):900–8.
- Etchevers HC. Hiding in plain sight: molecular genetics applied to giant congenital melanocytic nevi. *J Invest Dermatol*. 2014;134(4):879–82.
- Rouillé T, Aractingi S, Kadlub N, Fraitag S, How-Kit A, Daunay A, et al. Local inhibition of MEK/Akt prevents cellular growth in human congenital melanocytic nevi. *J Invest Dermatol*. 2019;139(9):2004–2015.e13.
- Choi YS, Erlich TH, von Franque M, Rachmin I, Flesher JL, Schiferle EB, et al. Topical therapy for regression and melanoma prevention of congenital giant nevi. *Cell*. 2022;185(12):2071–2085.e12.
- Basu D, Salgado CM, Bauer B, Hoehl RM, Moscinski CN, Schmitt L, et al. Histone deacetylase inhibitor Vorinostat (SAHA) suppresses microphthalmia transcription factor expression and induces cell death in nevocytes from large/giant congenital melanocytic nevi. *Melanoma Res*. 2021;31(4):319–27.
- André F, Ciruelos E, Rubovszky G, Campone M, Loibl S, Rugo HS, et al. Alpelisib for *PIK3CA*-mutated, hormone receptor-positive advanced breast cancer. *N Engl J Med*. 2019;380(20):1929–40.
- Basu D, Salgado CM, Bauer B, Khakoo Y, Patel JR, Hoehl RM, et al. The dual PI3K/mTOR inhibitor Omipalisib/GSK2126458 inhibits Clonogenic growth in Oncogenically-transformed cells from Neurocutaneous Melanocytosis. *Cancer Genomics Proteomics*. 2018;15(4):239–48.
- Abengozar-Muela M, Esparza MV, Garcia-Ros D, Vázquez CE, Echeveste JI, Idoate MA, et al. Diverse immune environments in human lung tuberculosis granulomas assessed by quantitative multiplexed immunofluorescence. *Mod Pathol*. 2020;33(12):2507–19.
- Jiménez-Sánchez D, López-Janeiro Á, Villalba-Esparza M, Ariz M, Kadioglu E, Masetto I, et al. Weakly supervised deep learning to predict recurrence in low-grade endometrial cancer from multiplexed immunofluorescence images. *NPJ Digit Med*. 2023;6(1):48.
- Castellano E, Downward J. RAS interaction with PI3K: more than just another effector pathway. *Genes Cancer*. 2011;2(3):261–74.
- Lim KH, Counter CM. Reduction in the requirement of oncogenic Ras signaling to activation of PI3K/AKT pathway during tumor maintenance. *Cancer Cell*. 2005;8(381):92–392.
- Zhao JJ, Cheng H, Jia S, Wang L, Gjoerup OV, Mikami A, et al. The p110alpha isoform of PI3K is essential for proper growth factor signaling and oncogenic transformation. *Proc Natl Acad Sci U S A*. 2006;103(44):16296–300.
- Irvine CA, Adams DM, Ankrah NO, O'Connell P, López Gutiérrez JC. *Clinical benefit of alpelisib in pediatric patients with PIK3CA-related overgrowth spectrum (PROS): an EPIK-P1 analysis*. ESMO Congress. 2022.
- Posch C, Moslehi H, Feeney L, Green GA, Ebaee A, Feichtenschlager V, et al. Combined targeting of MEK and PI3K/mTOR effector pathways is necessary to effectively inhibit NRAS mutant melanoma in vitro and in vivo. *Proc Natl Acad Sci U S A*. 2013;110(10):4015–20.

**How to cite this article:** Tomás-Velázquez A, López-Gutiérrez JC, de Andrea C, Reyes-Múgica M, Salgado CM, Redondo P. Alpelisib decreases nevocytes of congenital melanocytic nevi. *J Eur Acad Dermatol Venereol*. 2023;00:1–5. <https://doi.org/10.1111/jdv.19736>